



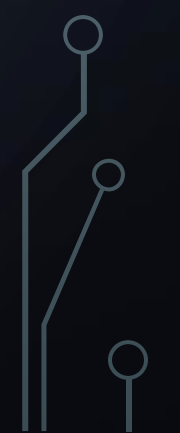

CHRONIC OBSTRUCTIVE PULMONARY DISEASE

DR:L.NAMVAR

PULMONOLOGIST

CLINICAL PRESENTATION



- COPD includes **emphysema**, an anatomically defined condition characterized by destruction of the lung alveoli with air space enlargement;
- **chronic bronchitis**, a clinically defined condition with chronic cough and phlegm;
- **small airway disease**, a condition in which small bronchioles are narrowed and reduced in number

- Chronic obstructive pulmonary disease (COPD) is defined as a disease state characterized by **persistent** respiratory symptoms and airflow limitation that is **not fully reversible**

CLINICAL PRESENTATION

- **■ HISTORY :**
- cough
- sputum production
- exertional dyspnea

PHYSICAL FINDINGS

- In the early stages of COPD, patients usually have an entirely normal physical examination.
- Current smokers may have signs of active smoking, including an **odor of smoke or nicotine staining of fingernails.**

- Some patients with advanced disease have **paradoxical inward movement** of the rib cage with inspiration (Hoover's sign), the result of alteration of the vector of diaphragmatic contraction on the rib cage as a result of chronic hyperinflation.

- Signs of overt right heart failure, termed **cor pulmonale**, are relatively infrequent since the advent of supplemental oxygen therapy. Clubbing of the digits is not a sign of COPD, and its presence should alert the clinician to initiate an investigation for causes of clubbing. In this population, the development of lung cancer is the most likely explanation for newly developed clubbing

- In patients with more severe disease, the physical examination of the lungs is notable for **a prolonged expiratory phase** and may include end expiratory **wheezing**. In addition, signs of hyperinflation include a **barrel chest and enlarged lung volumes** with poor diaphragmatic excursion as assessed by percussion.

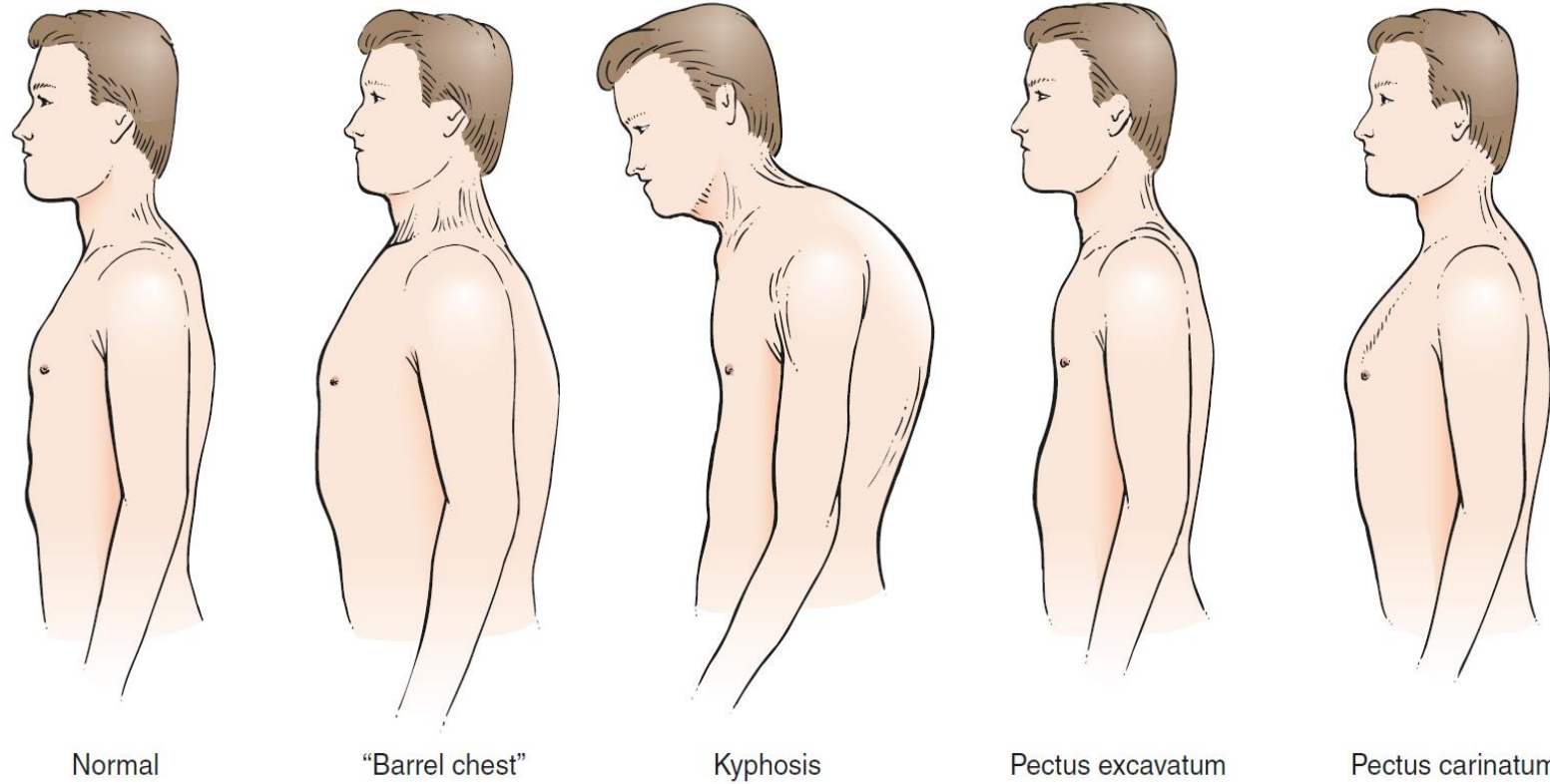
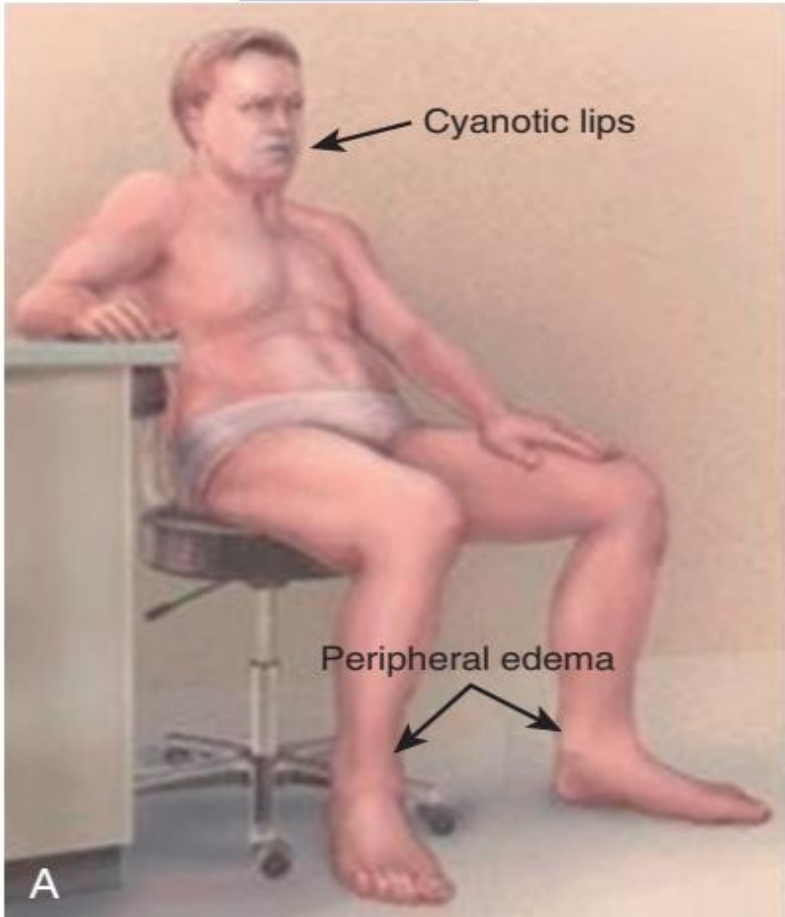


Figure 13-9 Common chest configurations.

- Patients with severe airflow obstruction may also exhibit use of **accessory muscles** of respiration, sitting in the characteristic **“tripod”** position to facilitate the actions of the sternocleidomastoid, scalene, and intercostal muscles. Patients may develop cyanosis, visible in the lips and nail beds

- **pink puffers** :thin and noncyanotic at rest and have prominent use of accessory muscles
- **Blue bloaters** : chronic bronchitis are more likely to be heavy and cyanotic

Blue bloater



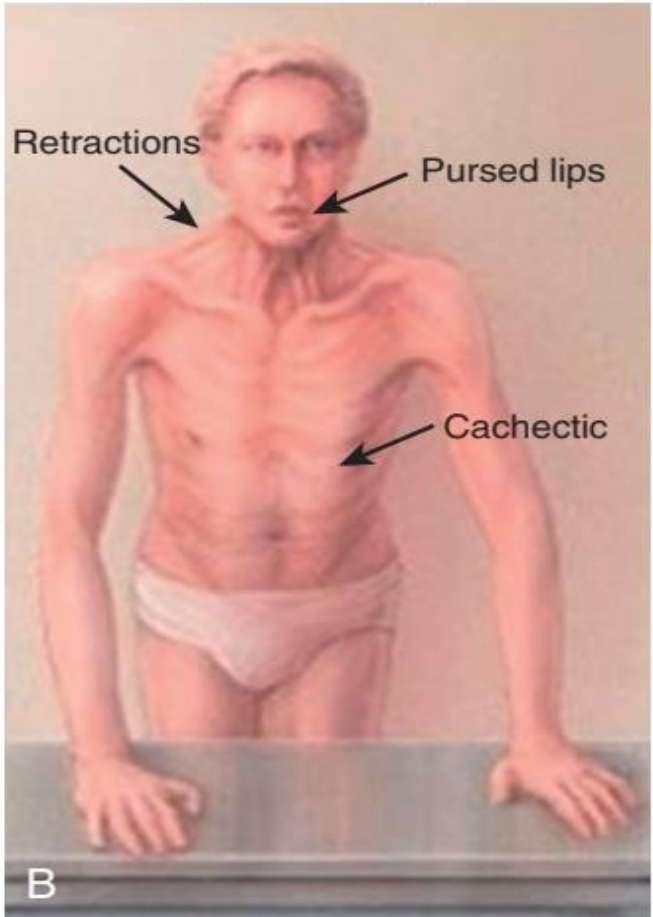
Cyanotic lips

Peripheral edema

A

No obvious increased work of breathing

Pink puffer



Retractions

Pursed lips

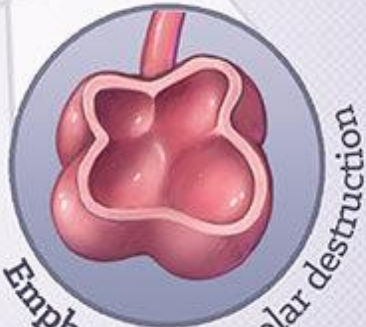
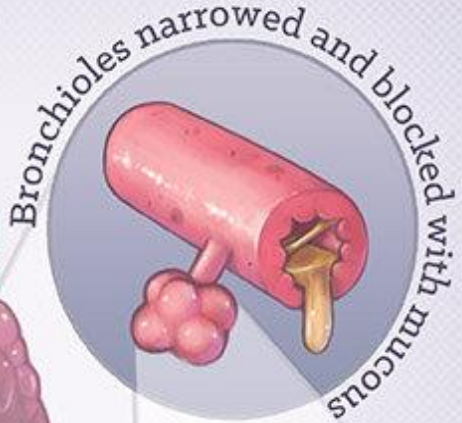
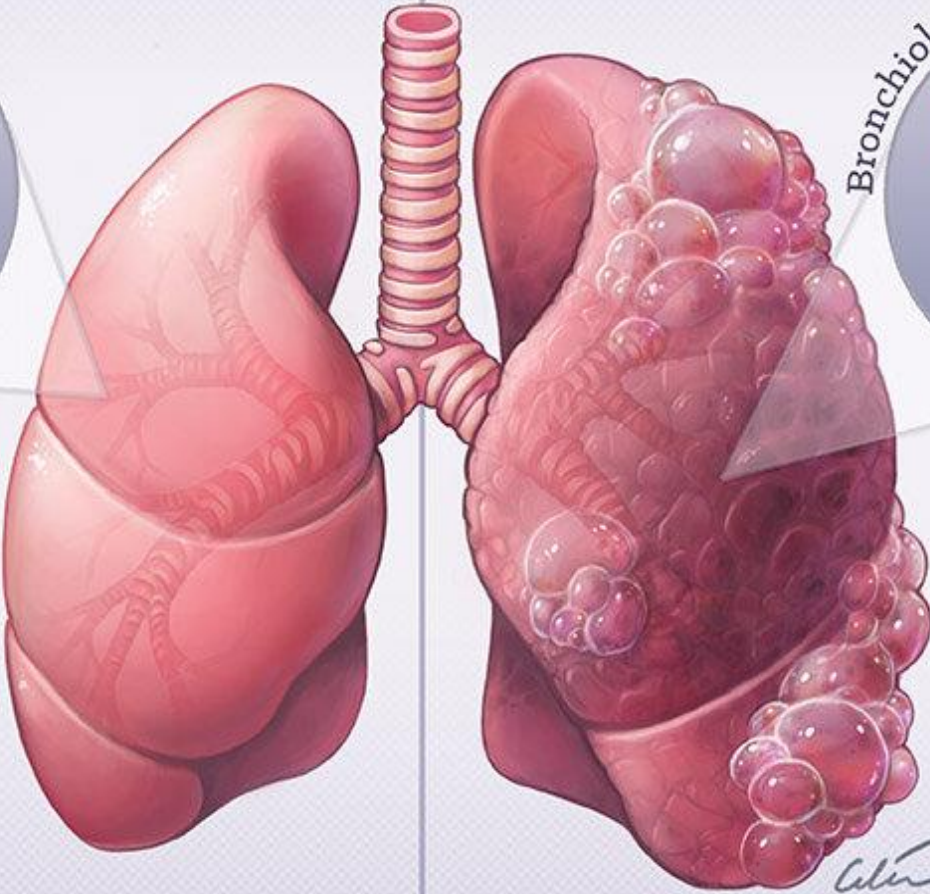
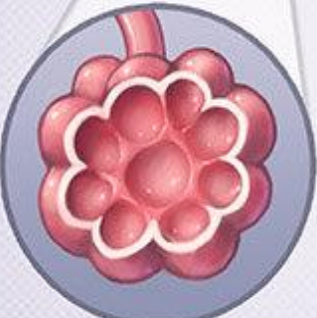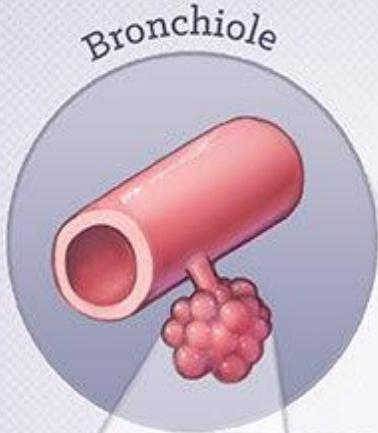
Cachectic

B

Obvious increased work of breathing

Health

COPD



Artwork

- Advanced disease may be accompanied by **cachexia**, with significant weight loss, bitemporal wasting, and diffuse loss of subcutaneous adipose tissue. This syndrome has been associated with both inadequate oral intake and elevated levels of inflammatory cytokines (**TNF- α**)

- It has been shown that a multifactorial index (**BODE**) incorporating airflow obstruction, exercise performance, dyspnea, and body mass index is a better predictor of mortality rate than pulmonary function alone

- Some patients with advanced disease have paradoxical inward movement of the rib cage with inspiration (**Hoover's sign**), the result of alteration of the vector of diaphragmatic contraction on the rib cage as a result of chronic hyperinflation.

LABORATORY FINDINGS

- The hallmark of COPD is airflow obstruction (discussed above). Pulmonary function testing shows airflow obstruction with a **reduction in FEV 1 and FEV1/FVC**

TABLE 286-1 GOLD Criteria for Severity of Airflow Obstruction in COPD

GOLD STAGE	SEVERITY	SPIROMETRY
I	Mild	$FEV_1/FVC < 0.7$ and $FEV_1 \geq 80\%$ predicted
II	Moderate	$FEV_1/FVC < 0.7$ and $FEV_1 \geq 50\%$ but $< 80\%$ predicted
III	Severe	$FEV_1/FVC < 0.7$ and $FEV_1 \geq 30\%$ but $< 50\%$ predicted
IV	Very severe	$FEV_1/FVC < 0.7$ and $FEV_1 < 30\%$ predicted

ARTERIAL BLOOD GASES AND OXIMETRY

- The change in **pH with Pco₂ is 0.08 units/10 mmHg acutely**
- and **0.03 units/10 mmHg** in the **chronic** state. Knowledge of the arterial pH therefore allows the classification of ventilatory failure, defined as Pco₂ >45 mmHg, into acute or chronic conditions with acute respiratory failure being associated with acidemia.

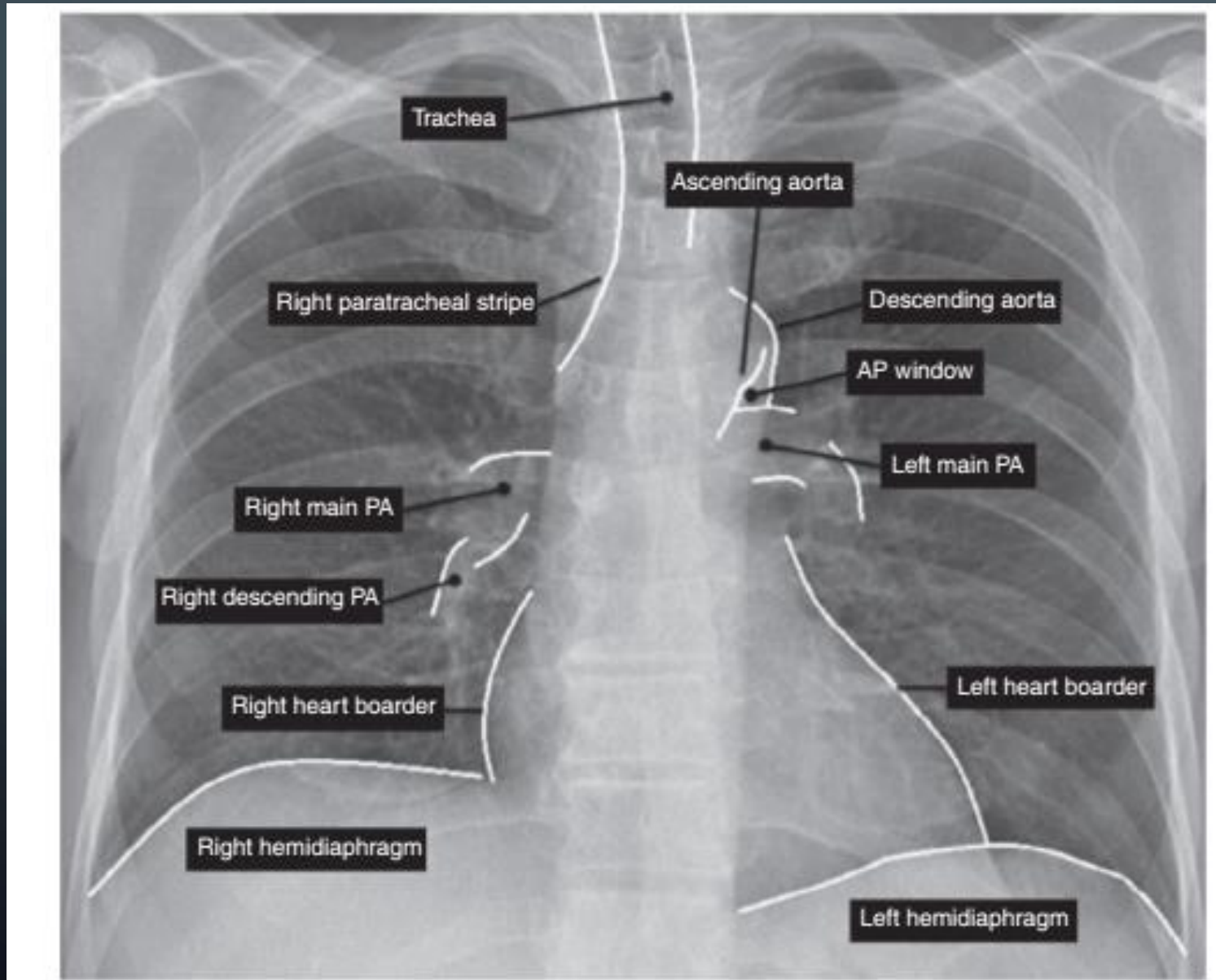
- An **elevated hematocrit** suggests the presence of chronic hypoxemia, as does the presence of signs of right ventricular hypertrophy

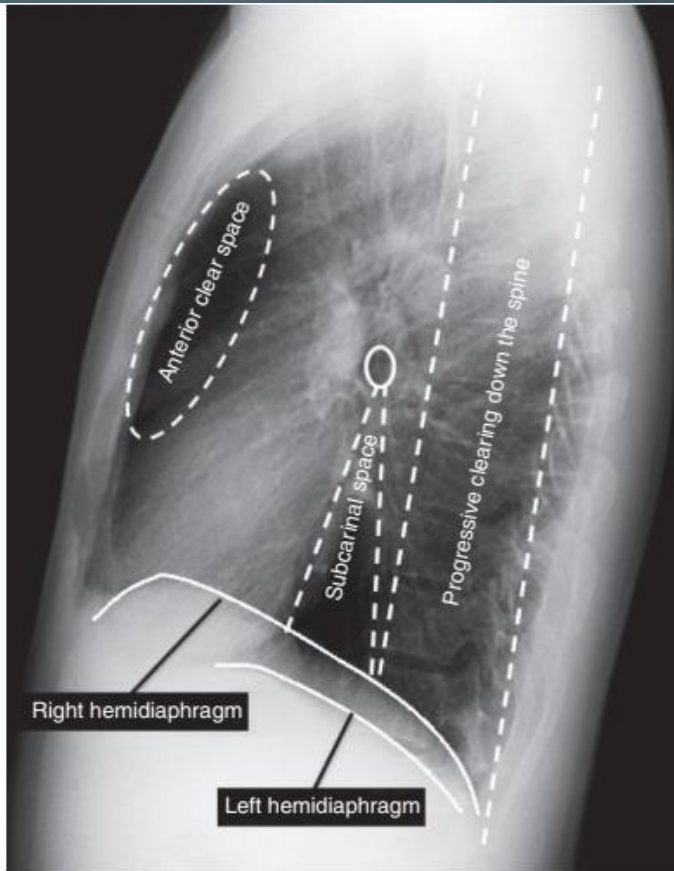
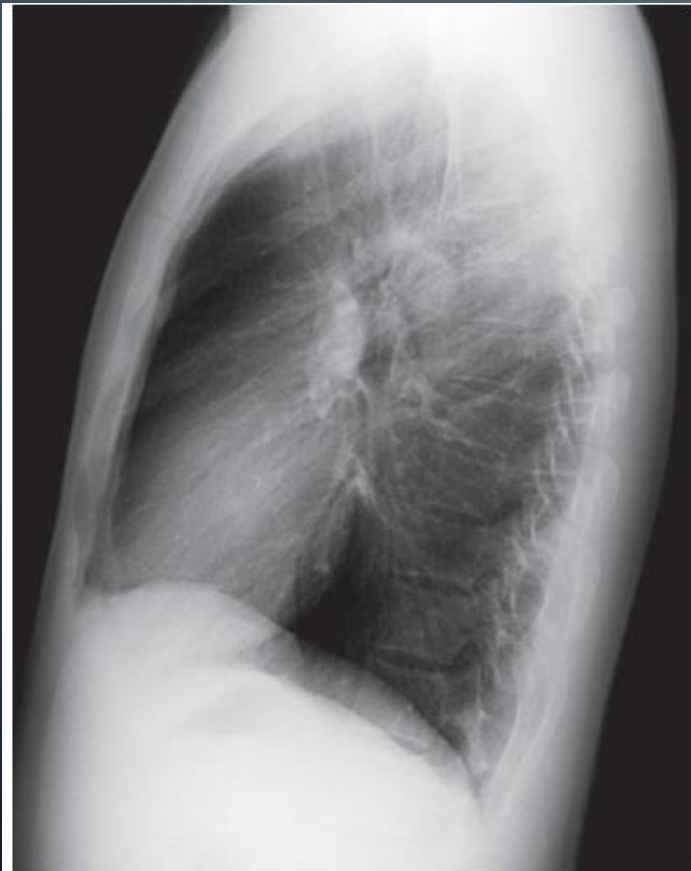ECG IN COPD

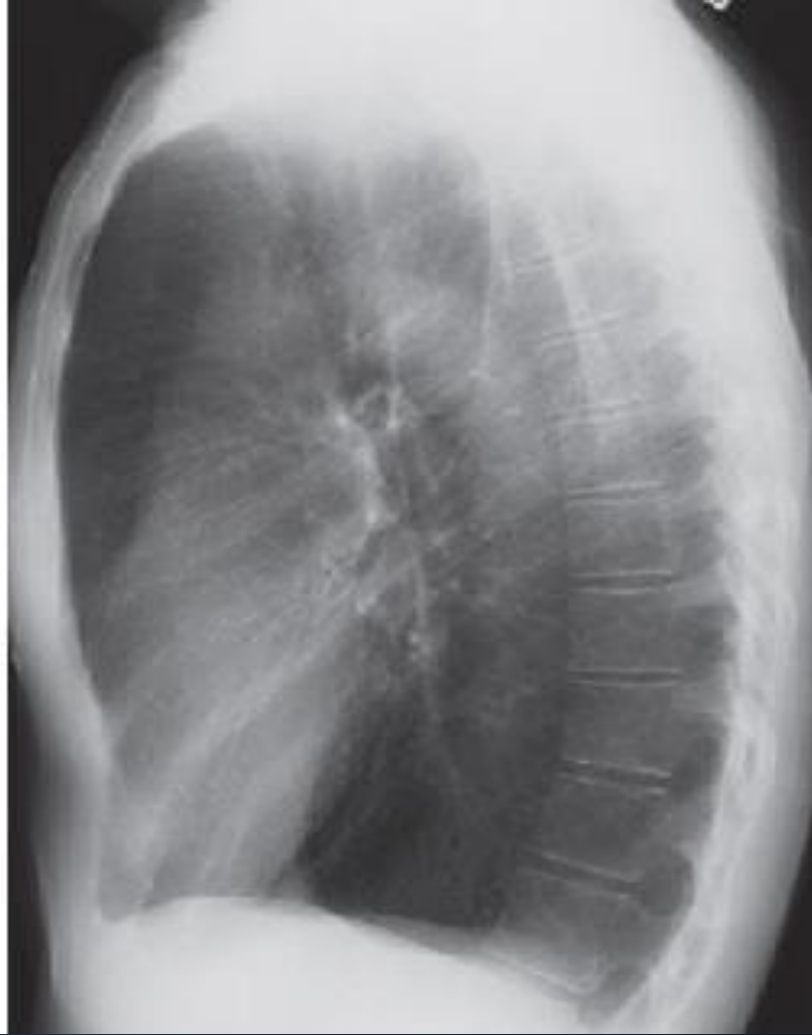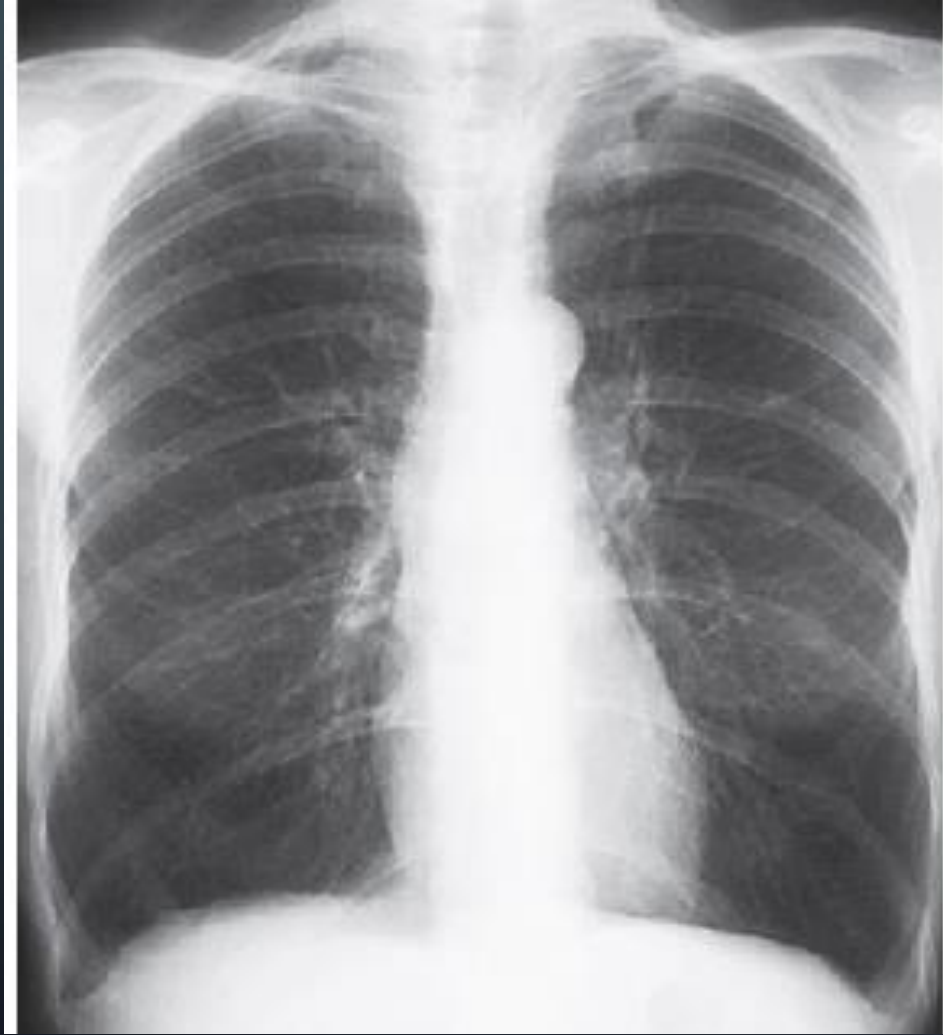- .Rt. Vent. Hypertrophy Rightward axis, R wave taller than the S wave in lead V 1, A persistent S wave into the lateral precordial leads. Incomplete right bundlebranch block pattern Rt. ventricular strain pattern (St seg. depression and Twave inversion in rt vent. leads)

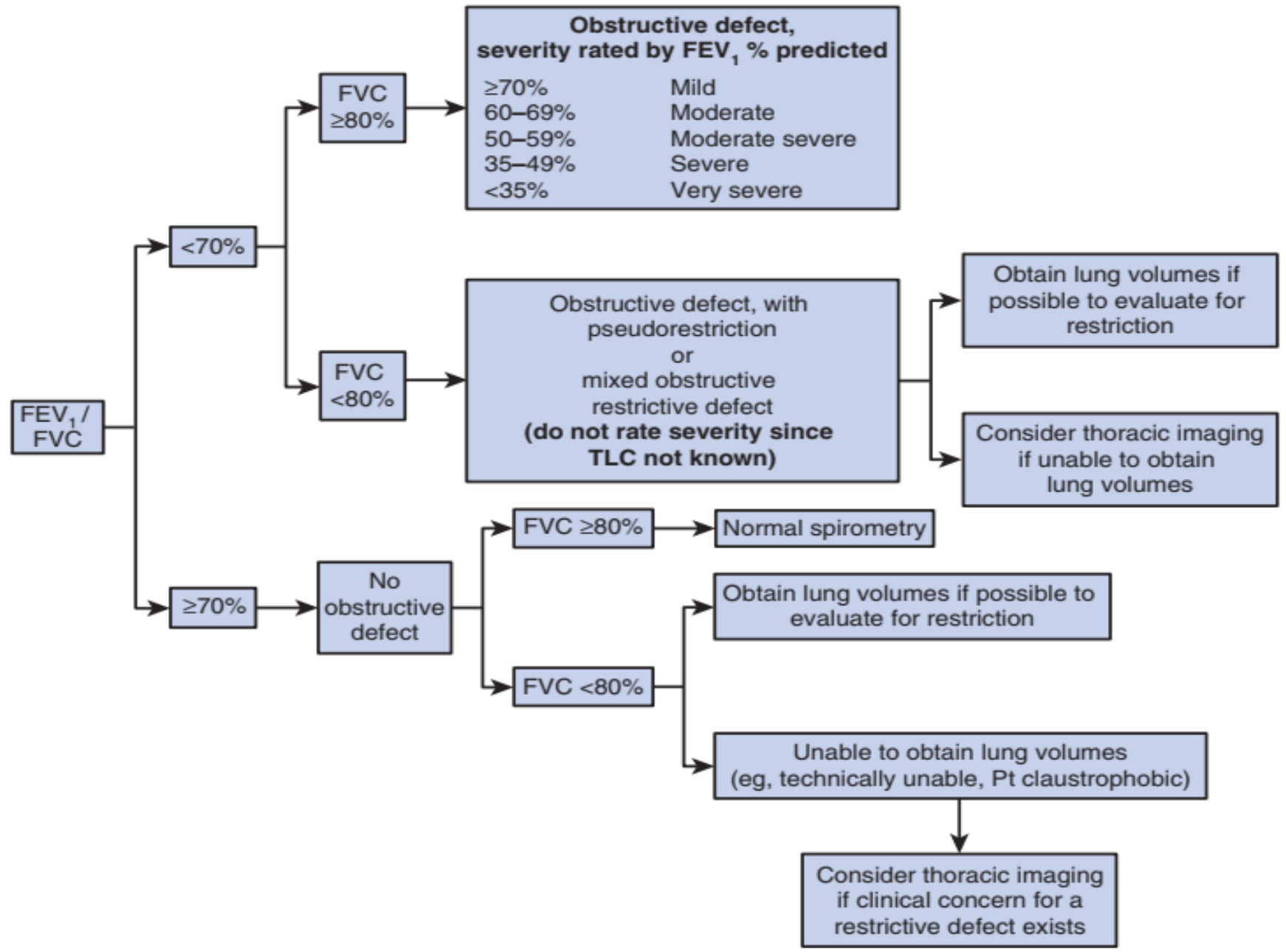
- Recent guidelines have suggested testing for **α 1 AT deficiency** in all subjects with COPD or asthma with chronic airflow obstruction

- Radiographic studies may assist in the classification of the type of COPD. **Obvious bullae**, paucity of parenchymal markings, or **hyperlucency** on chest x-ray suggests the presence of emphysema. Increased lung volumes and **flattening of the diaphragm** suggest hyperinflation but do not provide information about chronicity of the changes

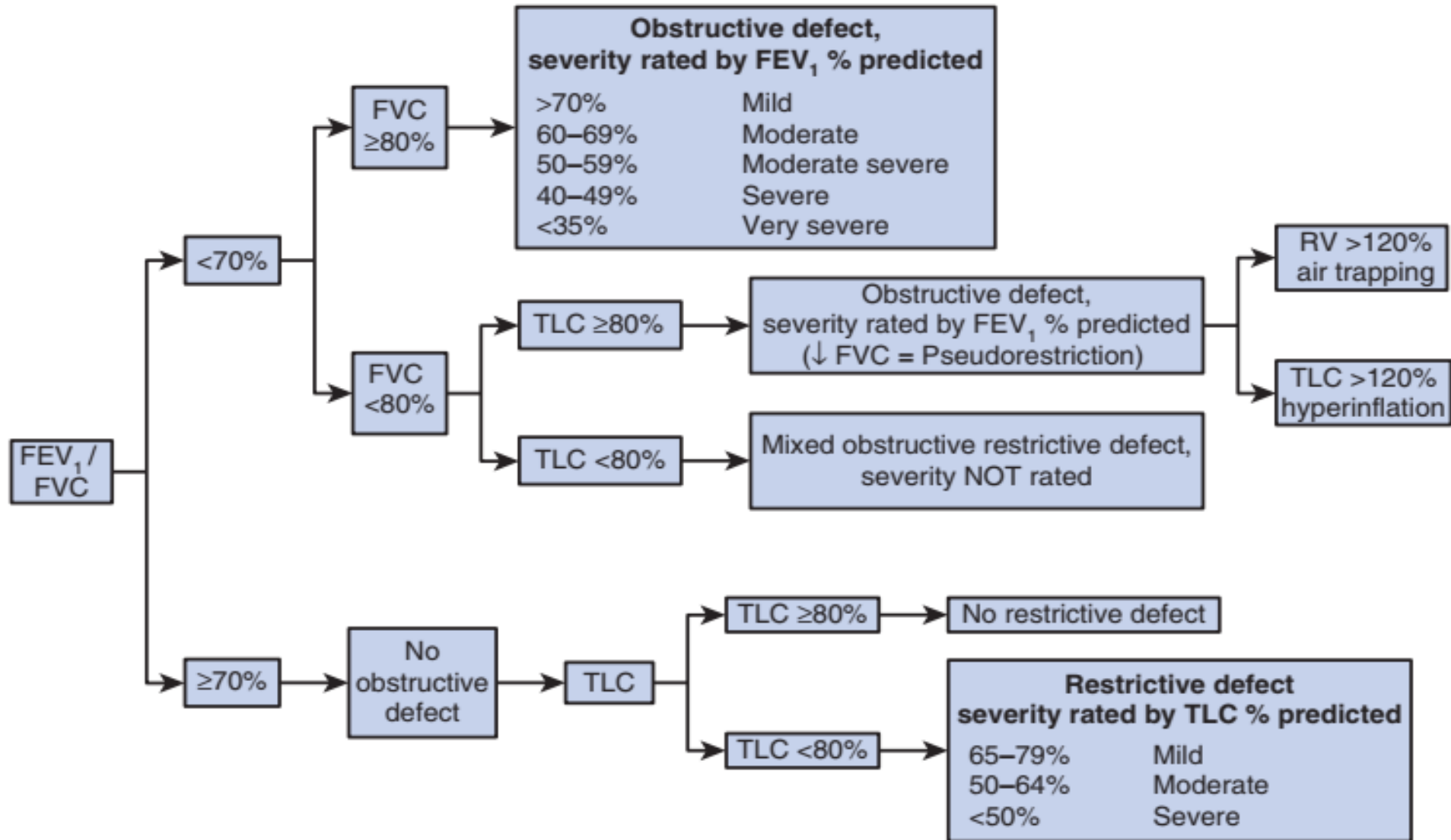


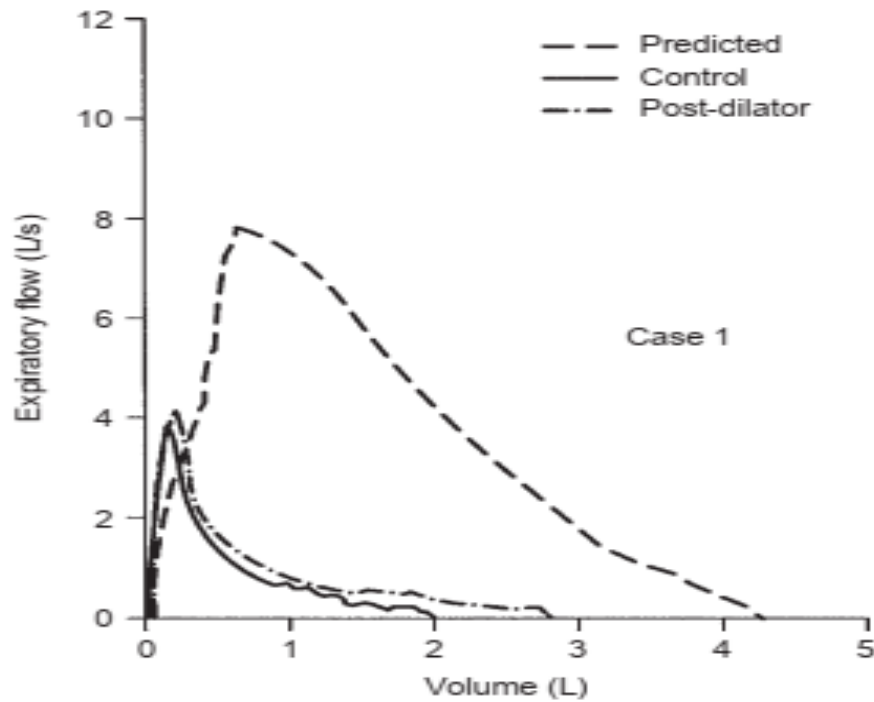






SPIROMETRY AND LUNG VOLUMES

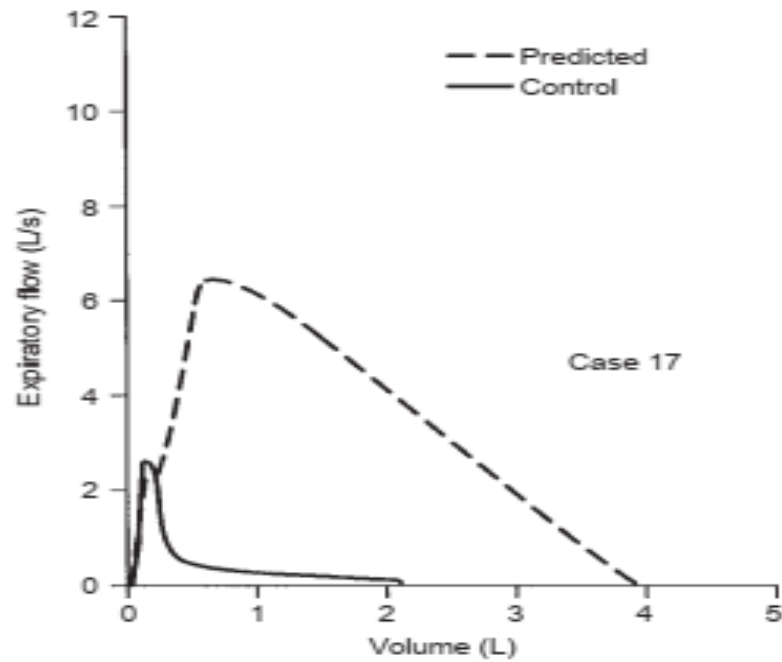




71 y M Wt 195 lb (88 kg) Ht 69 in. (175 cm) BMI 28.7 kg/m²

	Normal	Observed	% Predicted	Post-dilator
Spirometry				
FVC (L)	4.29	1.94*	45	2.76
FEV ₁ (L)	3.29	1.03*	31	1.25
FEV ₁ /FVC (%)	77	53*		
FEF ₂₅₋₇₅ (L/s)	2.8	0.4*	15	0.5
MVV (L/min)	125	51*	41	
Volumes				
TLC (L)	6.61	9.37*	142	
RV/TLC (%)	35	75*	214	
Dlco (mL/min/mm Hg)	25	10*	40	

Case 17



29 y F Wt 110 lb (50 kg) Ht 65 in. (165 cm) BMI 18.4 kg/m²

	Normal	Observed	% Predicted	Post-dilator
Spirometry				
FVC (L)	3.93	2.39*	61	2.86
FEV ₁ (L)	3.34	0.62*	19	0.67
FEV ₁ /FVC (%)	85	26*		
FEF ₂₅₋₇₅ (L/s)	3.4	0.2*	6	0.2
MVV (L/min)	119	28*	23	
Volumes				
TLC (L)	5.18	6.63	128	
RV/TLC (%)	24	59*	246	
Dlco (mL/min/mm Hg)	25	7*	28	

EXACERBATIONS OF COPD

- Exacerbations are episodic acute worsening of respiratory symptoms, including increased **dyspnea, cough, wheezing, and/ or change in the amount and character of sputum.**

- They may or may not be accompanied by other signs of illness, including **fever, myalgias, and sore throat**. The strongest single predictor of exacerbations is a history of a previous exacerbation. The frequency of exacerbations increases as airflow obstruction worsens; patients with severe (FEV1 reduction)

- Other factors, such as an **elevated ratio of the diameter of the pulmonary artery to aorta on chest CT**, and gastroesophageal reflux, are also associated with increased risk of COPD exacerbations.

PRECIPITATING CAUSES AND STRATEGIES TO REDUCE FREQUENCY OF EXACERBATIONS

- **bacterial infection/superinfection** is involved in >50% of exacerbations **Viral respiratory infections** are present in approximately one-third of COPD exacerbations. In a significant minority of instances (20–35%), no specific precipitant can be identified.

PATIENT ASSESSMENT

- The patient should be asked about **fever**; change in character of **sputum**; and associated symptoms such as **wheezing, nausea, vomiting, diarrhea, myalgias, and chills.**


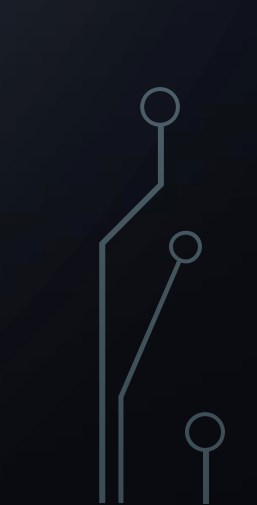
THE PHYSICAL EXAMINATION

- **tachycardia, tachypnea, use of accessory muscles, signs of perioral or peripheral cyanosis, the ability to speak in complete sentences, and the patient's mental status**

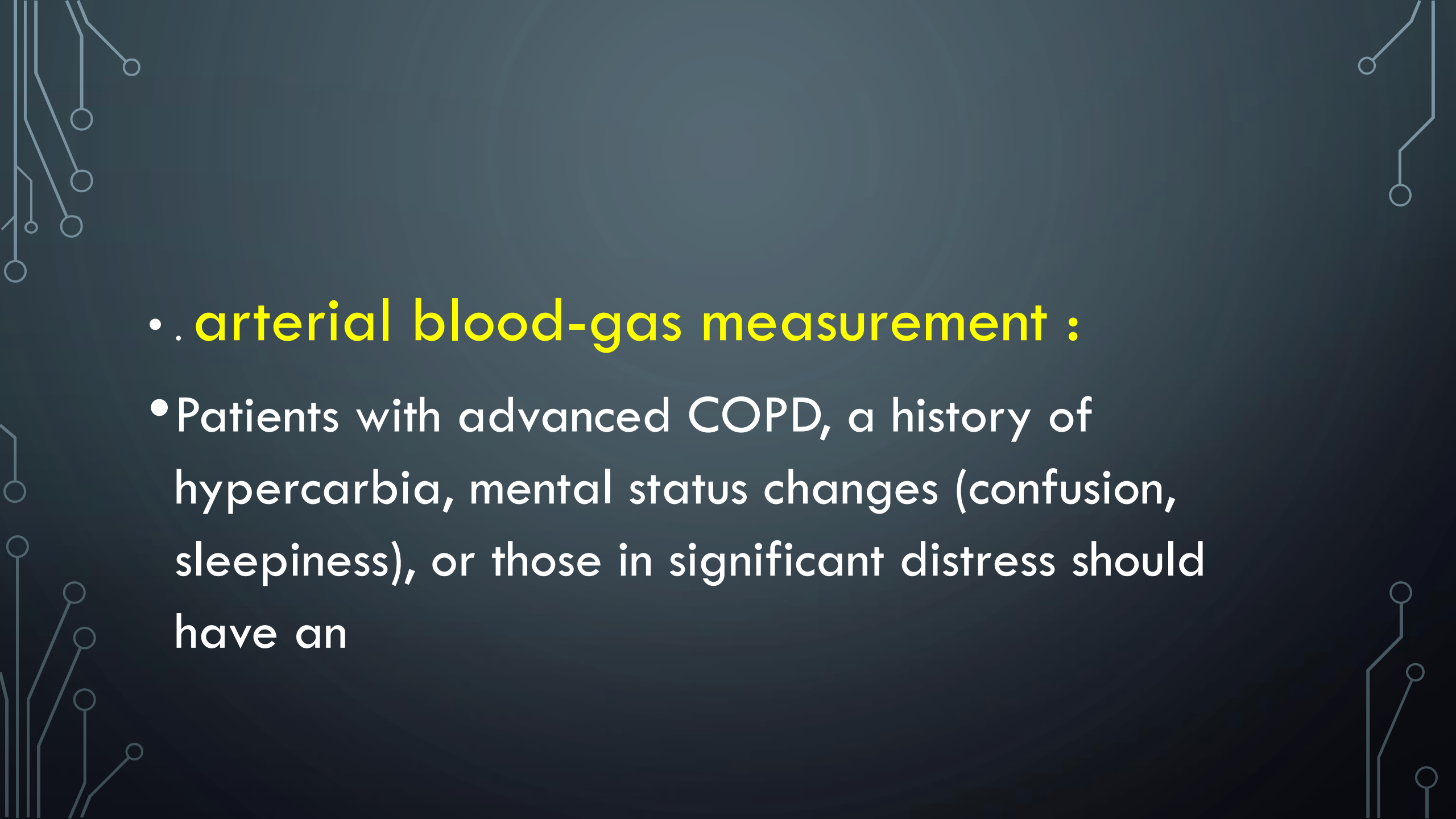
- The chest examination should establish the presence or absence of **focal findings**, degree of air movement, presence or absence of wheezing, **asymmetry** in the chest examination (suggesting large airway obstruction or pneumothorax mimicking an exacerbation), and the presence or absence of **paradoxical motion of the abdominal wall**



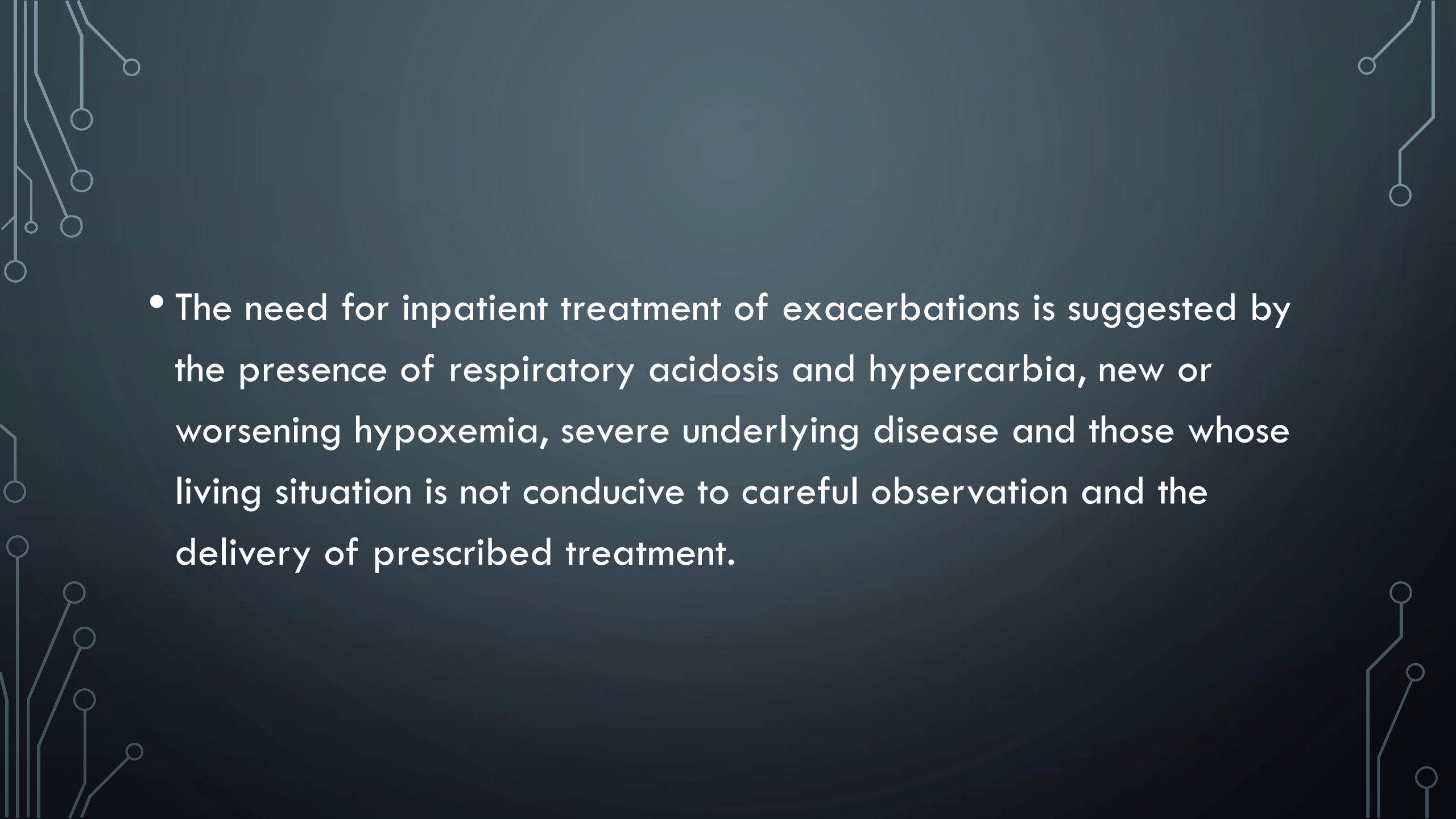
- **chest x-ray or chest CT scan:**

- Patients with severe underlying COPD, who are in moderate or severe distress, or those with focal findings should have a
- 
- 

- Approximately **25%** of x-rays in this clinical situation will be abnormal, with the most frequent findings being **pneumonia and congestive heart failure.**

- 
- The slide features a dark blue background with decorative white circuit-like lines in the corners. These lines consist of straight segments connected by small circles, resembling a network or data flow diagram.
- **arterial blood-gas measurement :**
 - Patients with advanced COPD, a history of hypercarbia, mental status changes (confusion, sleepiness), or those in significant distress should have an

- In contrast to its utility in the management of exacerbations of asthma, measurement of **pulmonary function has not been demonstrated to be helpful** in the diagnosis or management of exacerbations of COPD. Pulmonary embolus (PE) should also be considered, as the incidence of PE is increased in COPD exacerbations.

- 
- The need for inpatient treatment of exacerbations is suggested by the presence of respiratory acidosis and hypercarbia, new or worsening hypoxemia, severe underlying disease and those whose living situation is not conducive to careful observation and the delivery of prescribed treatment.